EXCLI Journal 2011;10:246-251 – ISSN 1611-2156
Received: October 28, 2011, accepted: November 20, 2011, published: November 24, 2011

Case report:

TWO CASES OF BRONCHIOLITIS OBLITERANS ORGANIZING PNEUMONIA SYNDROME AFTER POSTOPERATIVE IRRADIATION FOR BREAST CANCER

Sumito Inoue*, Michiko Nishiwaki, Koji Fukuzaki, Shuichi Abe, Yoko Shibata, Isao Kubota

Department of Cardiology, Pulmonology, and Nephrology, Yamagata University School of Medicine, Yamagata, Japan

* corresponding author; Sumito Inoue, 2-2-2, Iida-Nishi, Yamagata, 990-9585, Japan,
Tel; +81-23-628-5302, Fax; +81-23-628-5305, e-mail: sinoue@med.id.yamagata-u.ac.jp

ABSTRACT

We report two cases of bronchiolitis obliterans organizing pneumonia (BOOP) syndrome that developed after postoperative radiation therapy for breast cancer. In both patients, chest radiographs and computed tomography (CT) showed multiple consolidations outside the irradiation fields after several months of tangential radiation therapy. These patients were diagnosed as having radiation-associated BOOP syndrome, based on their clinical course and the findings on examination. After treatment with a systemic corticosteroid, radiographic consolidations and symptoms improved rapidly. In cases where consolidations appear outside the irradiated field, it is important to consider BOOP syndrome as a pulmonary complication of radiation therapy for breast cancer.

Keywords: Breast cancer, radiation therapy, BOOP (bronchiolitis obliterans organizing pneumonia) syndrome

INTRODUCTION

Postoperative radiotherapy is indicated for the management of breast cancer. The objective of radiotherapy for breast cancer is to minimize the risk of local or regional recurrence (Early Breast Cancer Trialists' Collaborative Group, 2005). Radiation injury to the lung has been described as the most important adverse consequence of radiotherapy of the lung fields (Kubo et al., 2009). Bronchiolitis obliterans organizing pneumonia (BOOP) was recently reported to develop outside the irradiation field. We report two cases of BOOP syndrome that occurred outside the irradiated field after several months of postoperative radiotherapy for breast cancer.

Case 1

A 66-year-old Japanese female complained of cough and sputum production for four weeks, commencing 23 weeks after receiving 50 Gy of tangential field irradiation for postoperative radiotherapy of right breast cancer. On admission to our hospital, her body temperature was 36.8 °C and oxyhemoglobin saturation was 95 % while breathing room air. Physical examination revealed a surgical scar on the right mammary gland. On auscultation, the lungs were clear and no cardiac murmurs were audible. Laboratory analyses showed increased levels of C-reactive protein (CRP), Krebs von den Lungen-6 (KL-6), and surfactant protein-D (SP-D). Chest radiography and computed tomography (CT) demonstrated multiple infiltrative shadows in the upper, middle and lower lobes of the right lung field (Figures 1a-c). Bacterial pathogens, includ-

EXCLI Journal 2011;10:246-251 – ISSN 1611-2156
Received: October 28, 2011, accepted: November 20, 2011, published: November 24, 2011

ing *Mycobacterium*, were not cultured from sputum. Histological findings from transbronchial lung biopsy revealed increased thickness of the alveolar walls and infiltration of lymphocytes into the alveoli. Analysis of bronchoalveolar lavage (BAL) fluid (3x50 ml from the right middle lobe) showed increased total cell counts and percentage of lymphocytes (total cells counts, 40.0×10^4/ml; macrophages, 50.5 %; neutrophils, 7.7 %; lymphocytes, 41.7 %; eosinophils, 0 %). Consolidation on the chest radiograph moved to other lung fields two weeks after admission (Figures 1d-f). BOOP syndrome was diagnosed on the basis of the clinical course and results of the examination. After treatment with 30 mg of systemic prednisolone, consolidation in the lung fields disappeared and the patient's symptoms improved.

Figure 1a

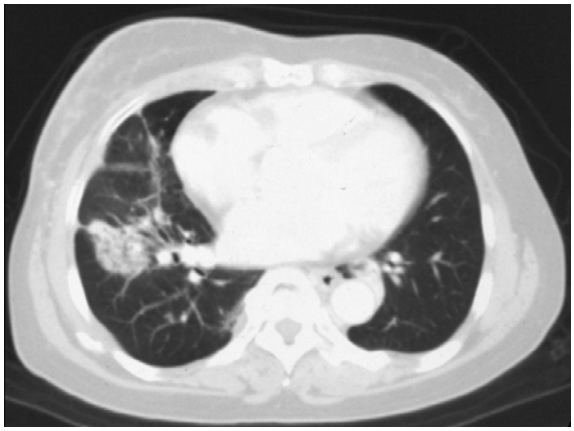

Figure 1b

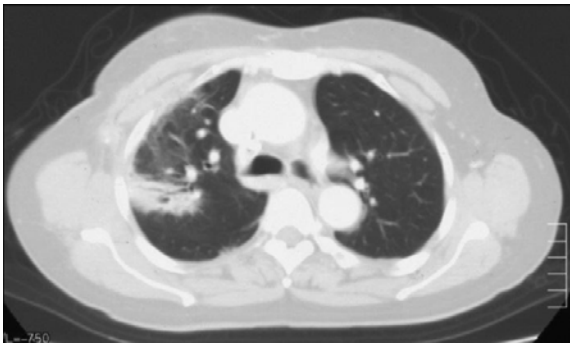

Figure 1c

Figure 1d

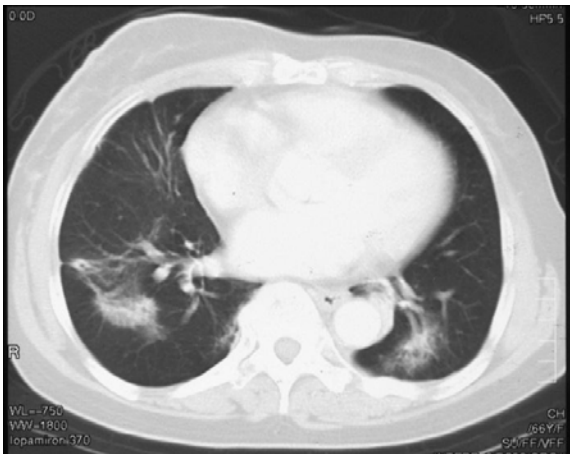

Figure 1e

EXCLI Journal 2011;10:246-251 – ISSN 1611-2156
Received: October 28, 2011, accepted: November 20, 2011, published: November 24, 2011

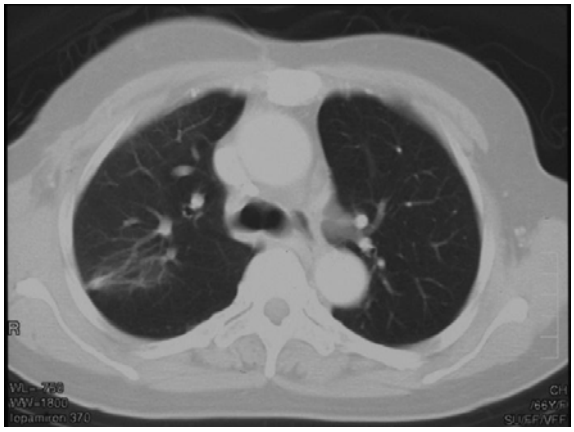

Figure 1f

Figure 1:
Case 1: Chest radiograph (a) and chest CT (b, c) obtained 27 weeks after irradiation, showing infiltration of the right upper and lower lung fields. Mobile infiltrative shadows were observed in the right and left lower lobes after 29 weeks of irradiation (d, e, f).

Case 2

A 65-year-old Japanese female was admitted to our hospital with pyrexia, cough and dyspnea which continued for two weeks, and commencing 26 weeks after she received 50 Gy of tangential field irradiation for postoperative radiotherapy of right breast cancer. On admission, her body temperature was 37.6 °C, and oxyhemoglobin saturation was 97 % while breathing room air. Physical examination revealed a surgical scar on the right mammary gland. On auscultation, the lungs were clear and no cardiac murmurs were audible. Laboratory analyses showed increase levels of CRP. Chest radiography and CT demonstrated multiple infiltrative shadows in the upper and lower lobes of the right lung field (Figures 2a-c). Bacterial pathogens, including *Mycobacterium*, were not cultured from sputum. Histological findings from transbronchial lung biopsy revealed increased thickness of the alveolar walls and infiltration of macrophages, lymphocytes and eosinophils into the alveoli. Analysis of BAL fluid (3×50 ml, from the right middle lobe) did not show any significant findings (total cells count, 8.0×10^4/ml; macrophages, 71.4 %; neutrophils, 7.4 %; lymphocytes, 19.8 %; eosinophils, 1.7 %). Consolidation on the chest radiograph moved to other lung fields two weeks after admission (Figures 2d-f). BOOP syndrome was diagnosed on the basis of the clinical course and results of the examination. After treatment with 30 mg of systemic prednisolone, consolidation in the lung fields disappeared and the patient's symptoms improved.

Figure 2a

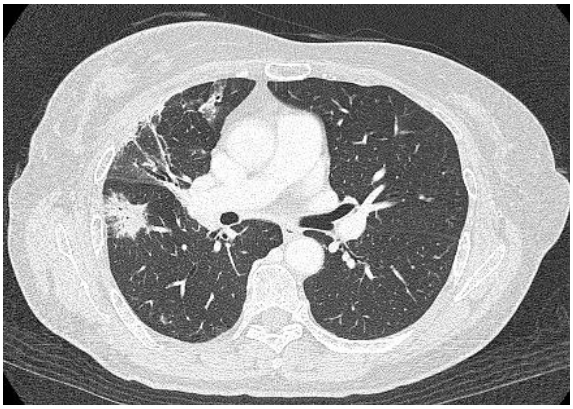

Figure 2b

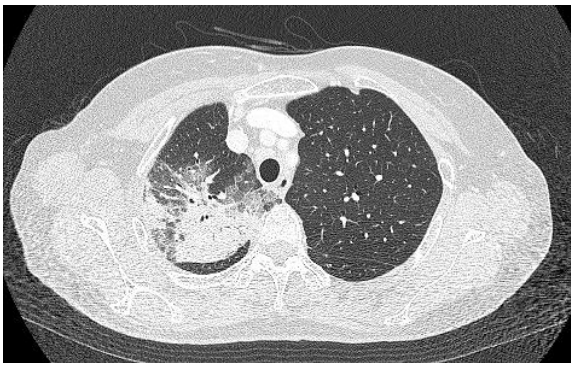

Figure 2c

Figure 2d

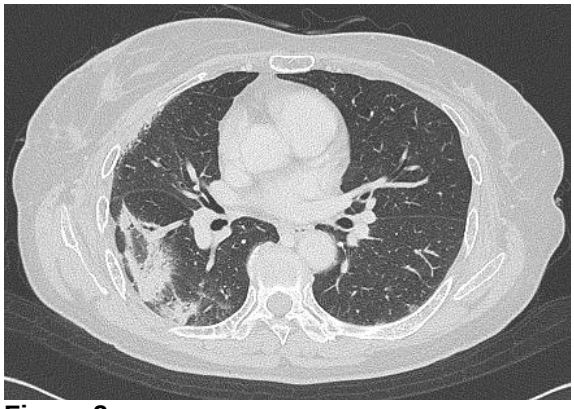

Figure 2e

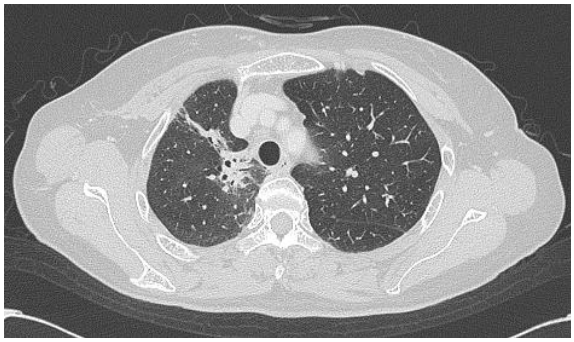

Figure 2f

Figure 2:
Case 2: Chest radiograph (a) and chest CT (b, c) obtained 26 weeks after irradiation, showing infiltration of the right upper, middle and lower lung fields. Mobile infiltrative shadows were observed in the right upper and lower lobes after 28 weeks of irradiation (d, e, f).

DISCUSSION

In recent years, breast-conserving surgery has become standard therapy for early stage breast cancer. The rates of local recurrence, as well as mortality, are decreased if radiotherapy is administered postoperatively (Early Breast Cancer Trialists' Collaborative Group, 2005). It is well known that radiotherapy for thoracic cancer may induce radiation pneumonitis. This occurs in the irradiated lung fields at an early time after radiotherapy (Kubo et al., 2009).

In 1990, Kaufman and co-worker first reported a case of BOOP that occurred one month after radiotherapy for small cell lung cancer (Kaufman and Komorowski, 1990). Some reports suggested that radiation injury occurring outside the irradiated lung fields should be diagnosed as BOOP syndrome. BOOP is characterized by symptoms of fever, cough, infiltrative shadows in the lung, and pathologically organizing granulation tissue, with migration of inflammatory cells into the alveolar spaces. BOOP is responsive to corticosteroid therapy, but not to antibiotic therapy (Epler et al., 1985).

The first report of BOOP syndrome after radiotherapy for breast cancer appeared in 1998 (Crestani et al., 1998). Crestani et al. defined four criteria for radiation-induced BOOP syndrome. First, it occurs within 12 months after irradiation. Second, systemic or respiratory symptoms such as fever or cough persist for more than two weeks. Third, infiltration of the lungs occurs outside the field of irradiation. Fourth, any other cause is excluded. Using these criteria, they identified 15 cases of radiation induced BOOP syndrome. Although these 15 cases showed some characteristics of BOOP syndrome, such as respiratory or systemic symptoms, or mobile infiltration of the lung, only five cases were proven to be BOOP based on histopathological findings. However, dramatic improvement was observed when these 15 patients received corticosteroid therapy. Crestani et al. (1998) pointed out that corticosteroid therapy would be effective in patients with radiation induced BOOP syndrome that matched their criteria, even without a histological diagnosis.

BOOP syndrome matching the criteria of Crestani et al. (1998) reportedly occurs

after radiotherapy in 2.3 to 2.5 % of breast cancer patients (Takigawa et al., 2000; Miwa et al., 2004; Katayama et al., 2009). The two cases reported here matched the criteria of Crestani et al. (1998). The cause of radiation associated BOOP syndrome is thought to be a combination of chemotherapy, endocrine therapy, and scattered radiation, but this has not been confirmed (Hamanishi et al., 2000; Ishimatsu et al., 2000; Kitagawa et al., 2003; Takai et al., 2006). Systemic corticosteroids are reported to be effective for the treatment of BOOP syndrome. However, some cases of recurrence after dose reduction or cessation of corticosteroid therapy have been reported (Miwa et al., 2004). In the present two cases, rapid improvements were observed with systemic corticosteroid therapy, and any signs of recurrence were recognized during the observation period.

In this report, we have presented two cases of BOOP syndrome associated with postoperative radiotherapy. Recently, irradiation after breast-conserving surgery has become standard therapy for early stage breast cancer. BOOP syndrome needs to be considered as a potential complication of radiation injury to the lung, even though it occurs outside the irradiated fields.

REFERENCES

Crestani B, Valeyre D, Roden S, Wallaert B, Dalphin JC, Cordier JF. Bronchiolitis obliterans organizing pneumonia syndrome primed by radiation therapy to the breast. Am J Respir Crit Care Med 1998;158: 1929-35.

Early Breast Cancer Trialists' Collaborative Group. Effects of radiotherapy and of differences in the extent of surgery for early breast cancer on local recurrence and 15-year survival: an overview of the randomised trials. Lancet 2005;366:2087-106.

Epler GR, Colby TV, McLoud TC, Carrington CB, Gaensler EA. Bronchiolitis obliterans organizing pneumonia. N Engl J Med 1985;312:152-8.

Hamanishi T, Gohma I, Oida K, Kori Y, Taguchi Y, Inoue T et al. Occurrence of BOOP outside radiation field after tangential radiation therapy for breast carcinoma. Nihon Kokyuki Gakkai Zasshi 2000;38: 551-6.

Ishimatsu Y, Iwashita T, Kaida H, Shikuwa C, Matsubara Y, Yoshinaga M et al. A case of radiation lung injury with characteristics of bronchiolitis obliterans organizing pneumonia after radiation therapy for breast carcinoma. Nihon Kokyuki Gakkai Zasshi 2000;38:610-4.

Katayama N, Sato S, Katsui K, Takemoto M, Tsuda T, Yoshida A et al. Analysis of factors associated with radiation-induced bronchiolitis obliterans organizing pneumonia syndrome after breast-conserving therapy. Int J Radiat Oncol Biol Phys 2009; 73:1049-54.

Kaufman J, Komorowski R. Bronchiolitis obliterans. A new clinical-pathologic complication of irradiation pneumonitis. Chest 1990;97:1243-4.

Kitagawa S, Aoshima M, Ohmagari N, Tada H, Chohnabayashi N, Suzuki K. Bronchiolitis obliterans organizing pneumonia after irradiation therapy for breast cancer. Nihon Kokyuki Gakkai Zasshi 2003;41:99-106.

Kubo A, Osaki K, Kawanaka T, Furutani S, Ikushima H, Nishitani H. Risk factors for radiation pneumonitis caused by whole breast irradiation following breast-conserving surgery. J Med Invest 2009;56:99-110.

Miwa S, Morita S, Suda T, Suzuki K, Hayakawa H, Chida K et al. The incidence and clinical characteristics of bronchiolitis obliterans organizing pneumonia syndrome after radiotherapy for breast cancer. Sarcoidosis Vasc Diffuse Lung Dis 2004;21:212-8.

Takai Y, Sato R, Sugino K, Nakata K, Kobashi Y, Uchida K. A case of cryptogenic organizing pneumonia after postoperative irradiation for breast cancer. Nihon Kokyuki Gakkai Zasshi 2006;44:55-60.

Takigawa N, Segawa Y, Saeki T, Kataoka M, Ida M, Kishino D et al. Bronchiolitis obliterans organizing pneumonia syndrome in breast-conserving therapy for early breast cancer: Radiation-induced lung toxicity. Int J Radiat Oncol Biol Phys 2000;48:751–5.