

Original article:

A COMPARATIVE STUDY PERTAINING TO DELETERIOUS EFFECTS OF DICLOFENAC SODIUM AND MELOXICAM ON KIDNEY TISSUE IN RATS

Sasan Andalib^{1,*}, Azadeh Motavallian Naeini^{2,*}, Alireza Garjani³, Naser Ahmadi Asl⁴, Ali Abdollahi⁵

¹ Veterinary Medicine School, Islamic Azad University of Tabriz, Tabriz, Iran

² Department of Pharmacology, School of Pharmacy and Pharmaceutical Sciences, Isfahan University of Medical Sciences, Isfahan, Iran

³ Department of Pharmacology, School of Pharmacy and Pharmaceutical Sciences, Tabriz University of Medical Sciences, Tabriz, Iran

⁴ Department of Physiology, School of Medicine, Tabriz University of Medical Sciences, Tabriz, Iran

⁵ Department of Anesthesiology, Baharestan Hospital, Isfahan, Iran

* corresponding authors:

¹ email: sasan.andalib@yahoo.co.uk; Tel.: +989123125064; Fax: +981312236752

² email: motavallian@pharm.mui.ac.ir; Tel.: +983117922628; Fax: +983116680011

ABSTRACT

NSAIDs (nonsteroidal anti-inflammatory drugs) are a class of drugs with analgesic, anti-inflammatory, and antipyretic effects. Diclofenac sodium is one of the world's most widely-prescribed NSAIDs. Meloxicam is another NSAID that was approved in the last several years. Treatment with NSAIDs may result in renal damage. Relatively, little is known about comparative nephrotoxicity of NSAIDs. Therefore, the present study was designed to compare the adverse effects of diclofenac sodium and meloxicam on renal tissue in rats.

Forty eight Wistar male rats were randomly assigned into 3 groups of 16 animals each. Group C served as normal control and received normal saline. Group D and M received diclofenac sodium (2.3 mg/kg/day) and meloxicam (2.3 mg/kg/day), respectively. After 17 days, all rats were scarified. Their kidneys were then harvested and processed for histological examination. In addition to cellular details, renal tubular count and diameter were assessed with the light microscope. The data were analyzed using SPSS software.

We found that the mean number of renal tubules was significantly lower in group D, than in group C. Moreover, the mean renal tubular diameter was significantly higher in group D than in group C.

The present study showed that a considerable degree of nephrotoxicity resulted from diclofenac sodium, compared to meloxicam. We suggest that diclofenac sodium can be replaced with meloxicam.

Keywords: NSAID, diclofenac sodium, meloxicam, kidney, renal tubules, nephrotoxicity

INTRODUCTION

NSAIDs (nonsteroidal anti-inflammatory drugs) are a class of drugs with analgesic, anti-inflammatory, and antipyretic effects (Litalien and Jacqz-Aigrain, 2001). The majority of NSAIDs inhibit the COX (cyclooxygenase) enzymes (Raz, 2002) and therefore influence the production of prostaglandins (Chandrasekharan et al., 2002), and in doing so, treatment with NSAIDs results in hepatic, gastrointestinal, and renal damage (McCarthy, 1998; Wolfe, 1998; Bjorkman, 1998; Fruchter et al., 2011). There are two isoforms of COX (Xie et al., 1991). COX1 is expressed in gastrointestinal tissue, in kidney and in platelets, and serves a protective and regulatory function (Smith and Dewitt, 1996). COX2 is present in low concentrations in most normal tissues such as kidney, liver, and lung (Seibert et al., 1994). The inflammatory process is also influenced by COX enzymes (Sano et al., 1992), especially COX2 (Crofford et al., 1994).

Diclofenac sodium (marketed under the trade names Cataflam and Voltaren) is one of the world's most widely-prescribed NSAIDs. Meloxicam (marketed under the brand name Mobic, among other names) is another NSAID that was approved in the last several years. Diclofenac sodium inhibits both COX1 and COX2 (Quiralte et al., 2007), however, meloxicam is a selective COX2 inhibitor (Furst, 1997; Gurocak et al., 2010). Compared to meloxicam, diclofenac sodium resulted in a high degree of nephrotoxicity (Swan et al., 2006). The damaging effects of diclofenac sodium and meloxicam on kidney tissue in human and animals is well-documented in the literature. Nevertheless, no single study exists that adequately compares the histopathological effects of these two NSAIDs on renal tissue. The present study compares the adverse effects of diclofenac sodium and meloxicam on kidney tissue in rats.

MATERIALS AND METHODS

Forty eight male 8-week-old Wistar rats (190 to 220 grams) were randomly assigned into 3 groups of 16 animals each. Group C served as normal control and received normal saline. Group D and M received diclofenac sodium (2.3 mg/kg/day) and meloxicam (2.3 mg/kg/day), respectively. Rats were housed under controlled environmental conditions with ambient temperature of 19 °C, relative humidity of 55±10 % and 12-h light/dark cycle. Standard pelleted chow and water were provided ad libitum. All the experimental procedures were conducted according to protocols approved by the Animal Care Committee of the Tabriz University of Medical Sciences. After a period of 17 days, rats were scarified. Their kidneys were then harvested and processed for histological examination. A full cross-sectional face of each kidney was processed and stained with PAS (Periodic Acid Schiff) and H&E (Hematoxylin & Eosin) and analyzed under Olympus light microscope. Using counting reticule, tubular count was made in five selected fields in the cortex of kidney. Tubular diameter was also measured by means of ocular micrometer. Finally, statistical analyses were performed using the SPSS statistical software package (Version 17.0). More precisely, data were analyzed by one-way ANOVA and Tukey post hoc tests, and P-value<0.05 was considered significant.

RESULTS

H&E staining showed that glomeruli and renal tubules were normal in group C. There was no sign of degeneration in the cortex and medulla of the kidneys. The mean number of convoluted tubules was 23.56. The mean tubular diameter was 51.1 µm. The basement membrane of tubules was quite normal. Moreover, PAS staining did not reveal any damage in brush border. The content of glycogen in proximal and distal tubules was fairly normal.

H&E staining revealed that nuclei were condensed in group D. Proximal and distal convoluted tubules were dilated. The mean tubular diameter was 53.1 μm . Degenerative changes were found in the proximal and distal convoluted tubules. The mean number of tubules was 21.31. PAS staining showed that the brush border was severely damaged at some places. The glycogen content was decreased in both proximal and distal tubules.

H&E staining showed that glomeruli and renal tubules were quite normal in group M. The mean number of renal convoluted tubules was 23.06. The mean renal tubular diameter was 51.9 μm . Any abnormality was not found in the basement membrane of renal cells. PAS staining revealed that the brush border was normal. There was a negligible decrease in the content of glycogen in the proximal and distal tubules.

Data analysis showed that the mean number of renal tubules was significantly lower in group D, than group C ($P=0.021$). In addition, the mean renal tubular diameter was significantly higher in group D than in group C ($P=0.003$).

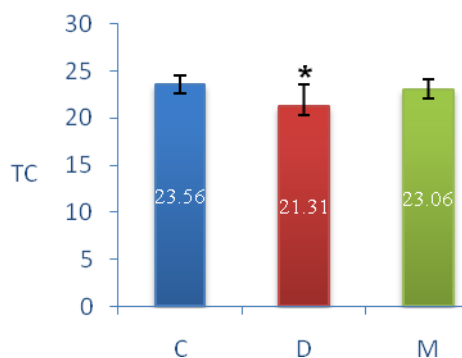


Figure 1: Comparison of tubular count (TC) between control (C), diclofenac sodium (D), and meloxicam (M) groups (mean \pm standard deviation)

* P -value <0.05 compared to control group (based on Tuckey post hoc test)

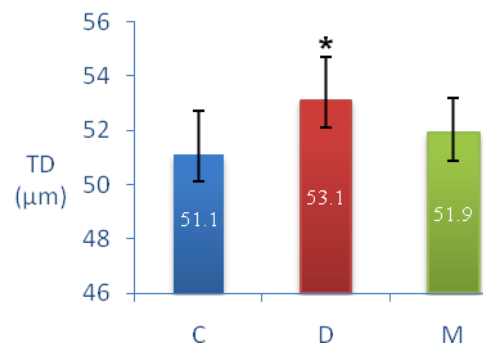


Figure 2: Comparison of tubular diameter (TD) between control (C), diclofenac sodium (D), and meloxicam (M) groups, (mean \pm standard deviation)

* P -value <0.05 compared to control group (based on Tuckey post hoc test)

DISCUSSION

Renal prostaglandins have crucial local functions. Prostaglandins are present in different parts of kidney such as glomeruli and convoluted tubules (Bonvalet et al., 1987; Farman et al., 1987; Stahl et al., 1984). Prostaglandin inhibitors have various physiologic effects (Flower, 1974). It is generally thought that NSAIDs have nephrotoxic impacts. Some studies were conducted on the adverse effects of NSAIDs on kidney (Hickey et al., 2001; Swan et al., 2006), Nonetheless, little is known about comparative deleterious effects of NSAIDs on renal tissue. Hence, present study was undertaken to investigate the nephrotoxic potential of diclofenac sodium and meloxicam.

We observed that the number of distal and proximal convoluted tubules was significantly less in group D as compared to group C. Our results seem to be consistent with other research which found that renal tissue was damaged by treatment with diclofenac sodium (Aydin et al., 2003). It was suggested that the diclofenac-induced renal damage may be associated with ischemia caused by inhibition of prostaglandins synthesis in renal arterioles (Yasmeen et al., 2007). It was shown that Indomethacin, which is an NSAID, resulted in vacuolar degeneration of proximal tubules and focal tubular atrophy (Gary et al., 1980; Clive

and Stoff, 1984). We observed that proximal and distal convoluted tubules were significantly dilated in Group D, in comparison with group C. Our results corroborated the findings of Scott (1966), who reported that diclofenac sodium resulted in transient shedding in renal cells. Another study indicated that treatment with diclofenac sodium gave rise to necrosis of endothelial cells in the renal corpuscles (Triebkorn et al., 2004). Furthermore, we did not find any significant renal tissue damage in group M. However, Rauser et al. (2010) reported that there was mild renal tubular damage in meloxicam-treated pigs. Ng et al. (2008) reported that diclofenac sodium resulted in severe renal damage. They also suggested that diclofenac sodium can be replaced with meloxicam.

In conclusion, the results of the present study showed that a considerable degree of nephrotoxicity resulted from diclofenac sodium, compared to meloxicam. Therefore, we suggest that diclofenac sodium can be replaced with meloxicam. Finally, further research is needed on comparative adverse effects of other NSAIDs on renal tissue.

REFERENCES

Aydin G, Gokcimen A, Oncu M, Cicek E, Karahan N, Goklap O. Histopathologic changes in liver and renal tissues induced by different doses of diclofenac sodium in rats. *Turk J Vet Anim Sci* 2003;27:1131-40.

Bjorkman D. Nonsteroidal anti-inflammatory drug-associated toxicity of the liver, lower gastrointestinal tract, and esophagus. *Am J Med* 1998;105(5):17S-21S.

Bonvalet JP, Pradelles P, Farman N. Segmental synthesis and actions of prostaglandins along the nephron. *Am J Physiol Renal Physiol* 1987;253:F377-87.

Chandrasekharan NV, Dai H, Roos KL, Evanson NK, Tomsik J, Elton TS, Simmons DL. COX-3, a cyclooxygenase-1 variant inhibited by acetaminophen and other analgesic/antipyretic drugs: Cloning, structure, and expression. *Proc Natl Acad Sci USA* 2002;99:13926-31.

Clive DM, Stoff JS. Renal syndromes associated with nonsteroidal anti-inflammatory drugs. *N Engl J Med* 1984;310:563-72.

Crofford LJ, Wilder RL, Ristimäki AP, Sano H, Remmers EF, Epps HR, Hla T. Cyclooxygenase-1 and -2 expression in rheumatoid synovial tissues. Effects of interleukin-1 beta, phorbol ester, and corticosteroids. *J Clin Invest* 1994;93:1095-101.

Farman N, Pradelles P, Bonvalet JP. PGE2, PGF2 alpha, 6-keto-PGF1 alpha, and TxB2 synthesis along the rabbit nephron. *Am J Physiol Renal Physiol* 1987;252:F53-9.

Flower RJ. Drugs which inhibit prostaglandin biosynthesis. *Pharmacol Rev* 1974;26:33-67.

Fruchter LL, Alexopoulou I, Lau KK. Acute interstitial nephritis with acetaminophen and alcohol intoxication. *Ital J Pediatr* 2011;37:17.

Furst DE. Meloxicam: selective COX-2 inhibition in clinical practice. *Semin Arthritis Rheum* 1997;26:21-7.

Gary NE, Dodelson R, Eisinger RP. Indomethacin-associated acute renal failure. *Am J Med* 1980;69:135-6.

Gurocak S, Ure I, Cumaoglu A, Gonul II, Sen I, Tan O, Aricioglu A, Bozkirli I. Renal tissue damage after experimental pyelonephritis: role of antioxidants and selective Cyclooxygenase-2 inhibitors. *Urology* 2010;76:508.e1-508.e5.

Hickey EJ, Raje RR, Reid VE, Gross SM, Ray SD. Diclofenac induced in vivo nephrotoxicity may involve oxidative stress-mediated massive genomic DNA fragmentation and apoptotic cell death. *Free Radical Bio Med* 2001;31:139-52.

Litalien C, Jacqz-Aigrain E. Risks and benefits of nonsteroidal anti-inflammatory drugs in children: a comparison with paracetamol. *Paediatr Drugs* 2001;3:817-58.

McCarthy D. Nonsteroidal anti-inflammatory drug-related gastrointestinal toxicity: definitions and epidemiology. *Am J Med* 1998;105(5):3S-9S.

Ng LE, Halliwell B, Wong KP. Nephrotoxic cell death by diclofenac and meloxicam. *Biochem Biophys Res Commun* 2008;369:873-7.

Quiralte J, Blanco C, Delgado J, Ortega N, Alcántara M, Castillo R, Anguita JL, Sáenz de San Pedro B, Carrillo T. Challenge-based clinical patterns of 223 Spanish patients with nonsteroidal anti-inflammatory-drug-induced-reactions. *J Investig Allergol Clin Immunol* 2007;17:182-8.

Rausser P, Stehlik L, Proks P, Srnec R, Necas A. Effect of seven-day administration of carprofen or meloxicam on renal function in clinically healthy miniature pigs. *Veterinari Medicina* 2010;55:438-44.

Raz A. Is inhibition of cyclooxygenase required for the antitumorigenic effects of nonsteroidal, anti-inflammatory drugs (NSAIDs)?: in vitro versus in vivo results and the relevance for the prevention and treatment of cancer. *Biochem Pharmacol* 2002;63:343-7.

Sano H, Hla T, Maier JA, Crofford LJ, Case JP, Maciag T, Wilder RL. In vivo cyclooxygenase expression in synovial tissues of patients with rheumatoid arthritis and osteoarthritis and rats with adjuvant and streptococcal cell wall arthritis. *J Clin Invest* 1992;89:97-108.

Scott JT. Phenacetin, aspirin and kidney damage. *Am Heart J* 1966;71:715-7.

Seibert K, Zhang Y, Leahy K, Hauser S, Masferrer J, Perkins W, Lee L, Isakson P. Pharmacological and biochemical demonstration of the role of cyclooxygenase 2 in inflammation and pain. *Proc Nat Acad Sci USA* 1994;91:12013-7.

Smith WL, Dewitt DL. Prostaglandin endoperoxide H synthases-1 and -2. *Adv Immunol* 1996;62:167-215.

Stahl RA, Paravicini M, Schollmeyer P. Angiotensin II stimulation of prostaglandin E2 and 6-keto-F1 alpha formation by isolated human glomeruli. *Kidney Int* 1984;26:30-4.

Swan G, Naidoo V, Cuthbert R, Green RE, Pain DJ, Swarup D, Prakash V, Taggart M, Bekker L, Das D, Diekmann J, Diekmann M, Killian E, Meharg A, Chandra Patra R, Saini M, Wolter K. Removing the threat of diclofenac to critically endangered Asian vultures. *PLoS Biol* 2006;4(3):e66.

Triebkorn R, Casper H, Heyd A, Eikemper R, Köhler HR, Schwaiger J. Toxic effects of the non-steroidal anti-inflammatory drug diclofenac Part II. Cytological effects in liver, kidney, gills and intestine of rainbow trout (*Oncorhynchus mykiss*). *Aquat Toxicol* 2004;68:151-66.

Wolfe MM. Future trends in the development of safer nonsteroidal anti-inflammatory drugs. *Am J Med* 1998;105(5):44S-52S.

Xie WL, Chipman JG, Robertson DL, Erikson RL, Simmons DL. Expression of a mitogen-responsive gene encoding prostaglandin synthase is regulated by mRNA splicing. *Proc Natl Acad Sci USA* 1991;88:2692-6.

Yasmeen T, Qureshi GS, Perveen S. Adverse effects of diclofenac sodium on renal parenchyma of adult albino rats. *J Pakistan Med Assoc* 2007;54:349-51.